



Content list Available at [ijmj.net](http://ijmj.net)  
**International Journal of  
Medical Justice**



Journal Homepage: <https://www.ijmj.net>

## Case Report

### Dyadic death - a case report

Haricharan A.\*, Pradipkumar Singh\*\*, Th. Meera Devi\*\*\*\*

\***Senior Resident**, Jawaharlal Institute Post Graduate Medical Education and Research (JIPMER) Karaikal, Pondicherry.

\*\***Assistant Professor**, \*\*\***Professor and Head**, Department of Forensic Medicine & Toxicology, Regional Institute of Medical Science, Imphal.

#### Article History:

Date of Submission: Friday December 23, 2022

Date of Start of Review Process: Friday December 23, 2022

Date of Receipt of Reviewers Report: Saturday December 31, 2022

Date of Revision: Thursday January 5, 2023

Date of Acceptance: Wednesday August 16, 2023

Date of Publication: Sunday December 15, 2023

Digital Object Identifier [DOI]: <https://doi.org/10.5281/zenodo>.

**Available Online:** Sunday December 24, 2023

**Website Archive:** <https://www.ijmj.net/archive/2023/2/IJMJ-2023-14.pdf>

**Citation:** A. Haricharan, Pradipkumar Singh, Th. Meera Devi. (2023). Dyadic death - a case report. International Journal of Medical Justice, 1(2): July-December 2023, 60-66. <https://doi.org/10.5281/zenodo>.

**Indexing:** Indexed in , , 

**Keywords:** Weapon of offence; heinous crime; Dyadic death

**Academic Editors:** Dr Suraj Sundaragiri

#### Correspondence:

**Dr A. Haricharan,**

Senior Resident

Jawaharlal Institute Postgraduate Medical Education and Research (JIPMER )  
Karaikal, Pondicherry

Email: [haricharanpr@gmail.com](mailto:haricharanpr@gmail.com) ORCID: 0000-0002-4330-0527

**Copyright:** © by the Publisher, IJMJ publishes all articles under a [Creative Commons Attribution \(CC BY\)](https://creativecommons.org/licenses/by/4.0/). 

**Abstract:** The death of two individuals in tandem or the suicide of the perpetrator after committing murder is defined as dyadic death. Though rarely seen, dyadic death is a tragic form of premeditated violence. The common agents used in such deaths include firearms, poisoning, hanging, drowning, etc., of which hanging and poisoning are considered as the preferred methods in India. The present case report is that of a family in which the father killed his two small children and tried to kill himself and his wife. It has been presented considering the uncommon occurrence of such cases in this part of the country as well as the heinous nature of crime and the uncommon weapon of offence used.

**Introduction:** Dyadic deaths (homicide-suicide): a dramatic violent event in which an individual kills another and subsequently commits suicide immediately or after a certain period, ranging from hours to 1 week. Types - spousal/consortium, familial, and extra-familial with different sub-classifications based on the motive of crime.<sup>1</sup> Dyadic deaths are relatively rare when compared to separate incidences of

homicide or suicide worldwide. The most common types of dyadic deaths involve the killing of intimate partners followed by killing family members, and perpetrators are mostly males.<sup>2</sup> Here, the case has been presented considering the uncommon occurrence of such cases in this part of the country as well as the heinous nature of the crime.

**Case Report:** In the latter part of March 2022 in Imphal, Manipur (INDIA), a man killed his two sons, aged 4 years and 2 years, then assaulted his wife and attempted to commit suicide by cutting his own throat. At the scene of the crime i.e., at home, the husband, wife and children were lying on the floor in a pool of blood and the room door was locked from the inside. The man and his wife were discovered in an unconscious state by neighbors and a blood-stained kitchen knife and hammer (Figure 1) were found near the hand of the man, while both the children were lying dead. No suicide note was found at the scene. Both husband and wife were taken to a nearby hospital. While recovering in the hospital, the man confessed to killing the children and assaulting his wife using a kitchen knife and hammer. The

dead bodies of both children were brought for medicolegal postmortem examination at our center. above the heel, red in color (Figure 4).

**Postmortem Examination Findings:**

The first child was male, about 4 years old. The body looks pale, postmortem staining was present at back, rigor mortis was developing, and dried blood stains were present on different parts of the body. **The external injuries as follow.**

1. Lacerated wound of the scalp over the left parietal region rounded in shape, situated 1 cm from the midline and 106cm above the heel, 2.5 cm x 3cm, brain depth with irregular margins associated with depressed open comminuted fractures of skull bones (Figure 2).
2. Lacerated wound of the scalp over the left frontal region, round in shape situated 1 cm from the midline, 101cm above the heel, 3.4cm x 3 cm, brain depth, with red irregular margins, associated with depressed open comminuted fractures of skull bones ( Figure 3).
3. Incised wound 3cmx 0.2cm x muscle depth, over the front of the neck, 3cm from the midline, 88cm above the heel and red in color. Incised wound 1.5cmx 0.2cm x skin depth, over the upper chest, 2.5cm right to the midline, 73cm

4. i) Wedge shape stab wound, 3.5cm x 0.2cm x cavity depth, obliquely placed over the right side of the back, the blunt medial edge was 2.8cm from the midline and the sharp lateral edge 3.5cm from the midline, 70 cm above the heel, red in color. (Figure5).

ii) stab wound 1.6cm x 0.2cmx skin depth, over the left side of the back, 7.5cm left to the midline, 75cm above the heel, red in color (Figure5).

5. In the skull, depressed open comminuted fractures of the frontal and left parietal bones radiate as multiple fissure fractures to both parietal and left temporal bones. Brain lacerated and contused both parietal and frontal bones (Figure 6).

The second child was also a male, aged around 2 years old. The body appears pale, bilateral conjunctiva appears pale, postmortem staining is present on the back and fixed, rigor mortis developing. Dried blood stains on different parts of the body.

**The external injuries are**

1. Incised wound, 4cmx 0.2cmx muscle depth , transversely placed over the front of the neck, across the midline, 60 cm above the heel, with sharp margins and tailing of

the wound on the left side red in color ( Figure 7).

2. i) stab wound, 4cm x 0.2cm, obliquely placed over the left side of the upper abdomen, the medial end 2cm from the midline, and the lateral end, 3.5cm from the midline, 48cm above the heel, wedge shape with a sharp acute edge on the lateral end and blunt medial edge, directed inferomedial cutting through the abdominal wall into the cavity with evisceration, of the intestines, red in color( Figure 8).

ii) Stab wound 5cmx 0.2cm obliquely placed over the left side of the umbilicus, the medial end 0.5cm from the midline and the lateral end 2.5cm from the midline, 38cm above the heel, wedge-shaped with a sharp acute edge on the lateral end and a blunt medial edge, directed inferomedial cutting through the abdominal wall into the cavity with evisceration of the intestines, red in color(Figure 8).

**Discussion:** Dyadic death episodes are reported from various parts of India and the demographic characteristics of perpetrators and victims are the same throughout the country, as observed in various reports. Extra familial incidents are rare

and in the majority of the cases, the offenders were males, mostly from a low socio-economic class, and less educated.<sup>3</sup> In our case too, the perpetrator was uneducated and belonged to a lower socioeconomic stratum. In developed countries, the use of firearms is a common method of homicide in dyadic deaths.<sup>4</sup> Deliberate neglect, throat splitting, starvation, smothering and drowning are common methods of killing a child. Moreover, in a patriarchal society like ours, a female child is more vulnerable to such violence. Interestingly, in our case, both the victims were small male children and an unusual combination of weapons of offence were used i.e., sharp as well as blunt weapons were used by the assailant for the gruesome murder.

Shooting (80.4%), sharp weapons (11%), hanging (6%), poisoning (4%), falls (3%), burns (1%), and vehicular accidents are methods of suicide in perpetrators.<sup>3</sup> In this case, the perpetrator attempted suicide by using a sharp weapon (kitchen knife), which is a common phenomenon in dyadic deaths. The causative factors are multidimensional for dyadic episodes and established breakdown in a relationship

(46%), mental illness (21%), physical ill health (11%) and financial stress (10%) are important reasons for homicide-suicide.<sup>5</sup> In our case, there was marital discord between the man and his wife, and he feared that his wife would leave him, so he took up the drastic step of committing such a heinous crime. Further, precipitating factors in dyadic deaths include prevailing circumstances and constant stress, which possibly end in tragedy.<sup>6</sup>

**Conclusion:** Dyadic deaths are uncommon and have been reported as stray incidents. In a patriarchal society, the killing of female children is reported from time to time. The unusual aspect of the case is that both the victims were very small male children brutally murdered by their own father using a combination of lethal weapons. The heinous nature of the crime observed, in this case, is a rarity and is worth reporting.

**Ethical Issues:** Ethical clearance is taken from Research Ethics Board Committee, RIMS, Imphal.

**Source of funding-** Nil

**Conflict of Interest** - Nil

**References:**

1. Mazruk P et al. The epidemiology of murder -suicide, J Am Med Assoc 1992, 267, 31: 79-83.

2. Berman AL, Dyadic death: a typology, Suicide Life Threat Behav. 1996; 26, 4:342- 50.
3. Bossarte RM, Simon RT , Barker L , Characteristic of homicide followed by suicide incidents in multiple states 2003 -04, Injury prevention 2006,12: ii 33-ii38.
4. Morton E , Rynyon CW, Moracco KE et al .Homicide - suicide involving female homicide victim ; population based study in north Carolina ,1988 ,13:91- 106.
5. Milroy CM et al, Reasons for homicide and suicide in episodes of dyadic death in Yorkshire and Humberside, Med Sci Law 1995, 35: 213 -217.
6. Graser RR, Family murder in South Africa: some possible explanations, Acta Criminology 1992 ,5 (19): 75 -80.

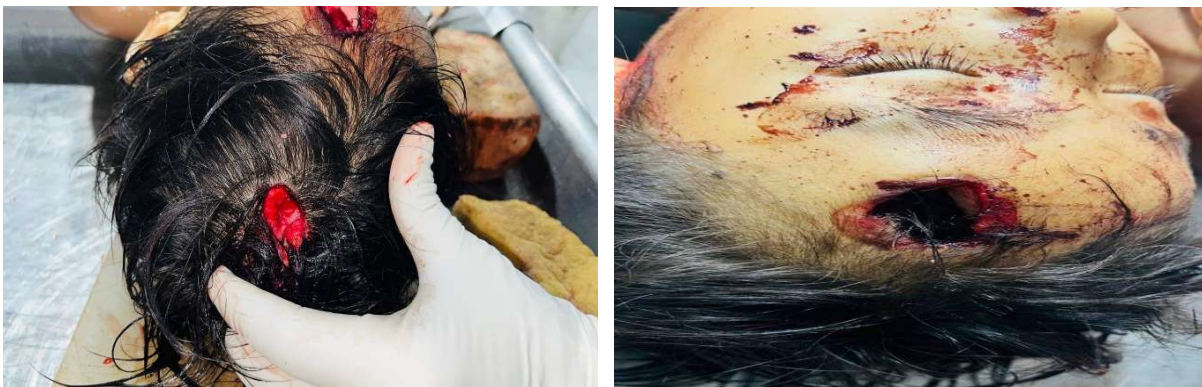**Disclaimer/Publisher's Note:** The information statements, opinions and data contained in all publications are solely those of the individual author(s) and contributor(s) and not of IJMJ and/or the editor(s). IJMJ and/or the editor(s) disclaim responsibility for any injury to people or property resulting from any innovation, ideas, methodology, instructions, conclusions, or products referred to in the content.

**Copyright:** © by the Publisher, IJMJ publishes all articles under a [Creative Commons Attribution \(CC BY\)](#) . Under the CC BY license, authors retain the copyright to their work while granting others the right to copy, distribute, display, and perform the work, as well as make derivative works based on it. All published articles, papers, and materials in the International Journal of Medical Justice, IJMJ are therefore freely accessible and shareable, provided appropriate attribution is given to the original authors.

**Figures: IJMJ-2023-14**

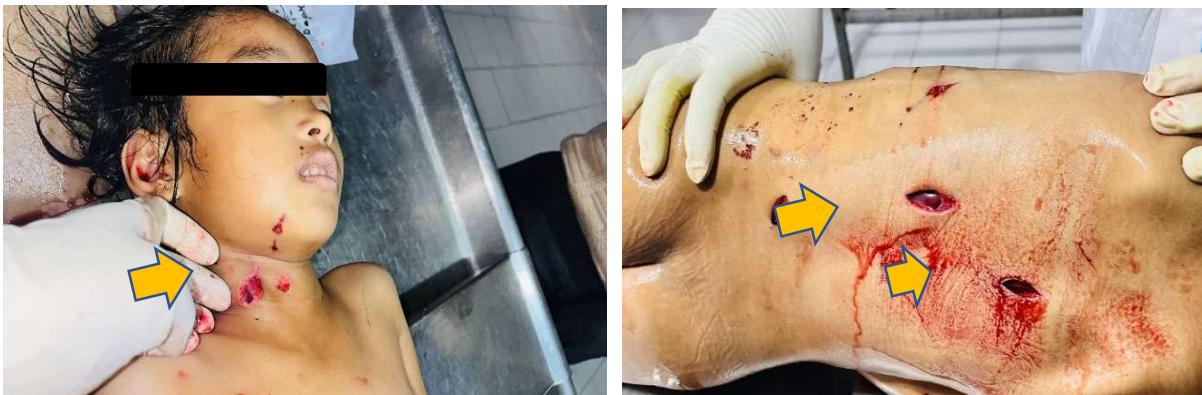

**Figure 1. Showing blood stained kitchen knife and hammer**



**Figure 2. Depressed open comminuted fractures of skull bones**

**Figure 3. Lacerated wound of the scalp over the left frontal region**



**Figure 4. Incised wound over the front of the neck**

**Figure 5. Wedge shape stab wound over the right and left back of the body**

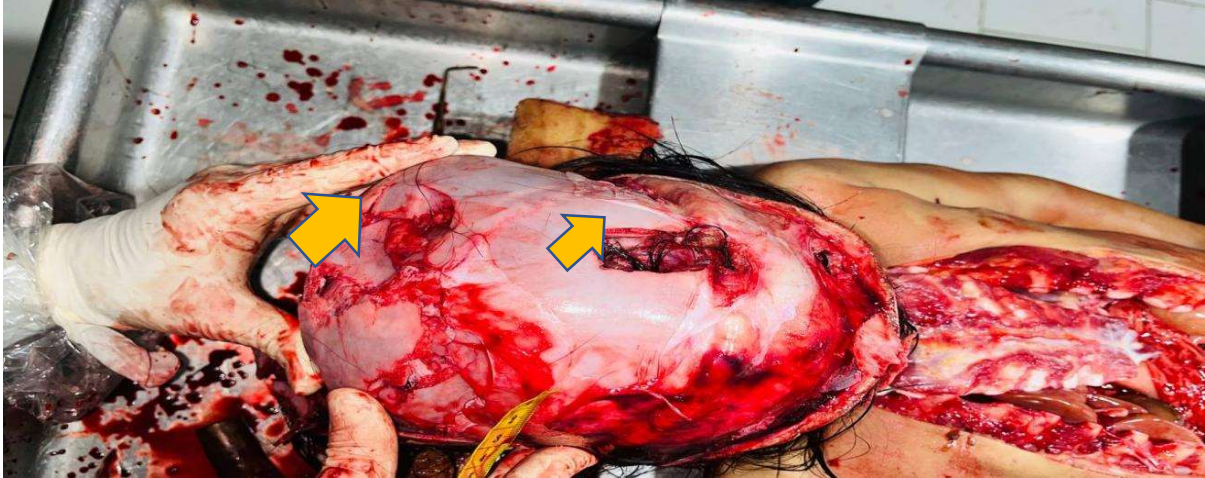


Figure 6. depressed open comminuted fractures of the frontal and left parietal bones

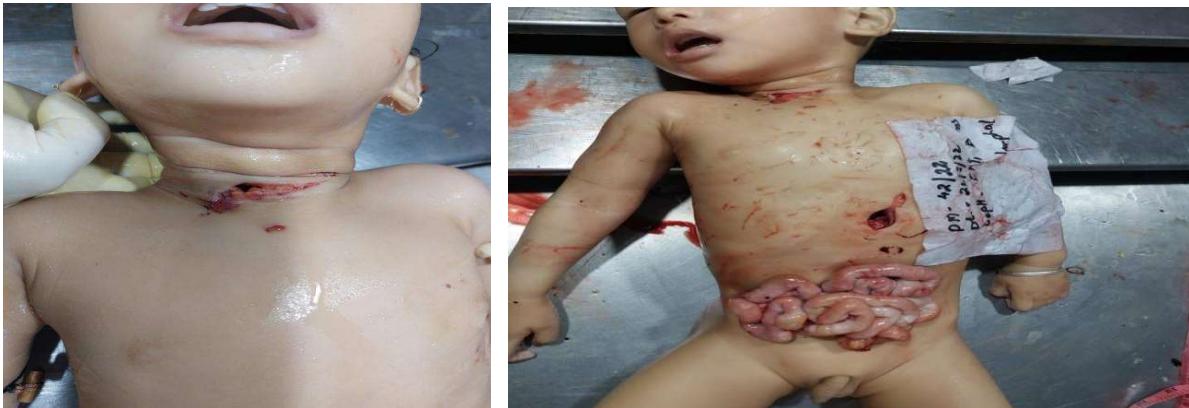

Figure 7. Incised wound, transversely placed over the front of the neck

Figure 8. Stab wound over the abdomen, evisceration of the intestines.